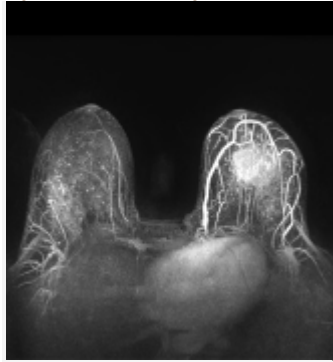


# MRI Improves Breast Cancer Screening in Older BRCA Carriers

News | January 05, 2015 | Breast Cancer, Screening

By Anna Azvolinsky, PhD



Adding an MRI to a mammogram improved the sensitivity of breast cancer...

Adding magnetic resonance imaging (MRI) to a mammogram improves the sensitivity of breast cancer screening in women 50 years of age or older who are *BRCA1* or *BRCA2* mutation carriers. While there is currently no consensus on whether the addition of MRI is necessary in breast screening protocols, these new results suggest that it should be reconsidered for this patient population, said the study authors.

The results were published in the *Journal of Clinical Oncology*.

Xuan-Anh Phi, Geertruida H. de Bock, of the University Medical Center Groningen in the Netherlands, and colleagues pooled individual patient data from six trials of high-risk patients that included those with *BRCA1* or *BRCA2* mutations. A total of 2,033 women were included in the analysis, patients had undergone at least one round of screening that included both a mammogram and an MRI. The combined screening method was done annually with the MRI and mammogram performed either on the same day or within 1 or 2 months of each other. A total of 1,951 women had both screenings.

The current study is the largest ever analysis of women with *BRCA1* or *BRCA2* mutations from high-risk trials, according to the authors.

For women at least 50 years of age, MRI plus mammography increased sensitivity compared with a mammogram alone (94.1% vs 38.1%,  $P < .001$ ).

MRI plus mammography was not significantly more sensitive than MRI alone (94.1% vs 84.4%,  $P = .28$ ).

Though it did not reach significance, the addition of MRI to mammography boosted breast screening sensitivity in women 50 and older to a level seen in younger patients (94.1% vs 93.2%;  $P = .79$ ).

Among all 184 patients who were found to have breast cancer, MRI alone detected cancer in 145 patients (78.8%) while mammography detected cancer in 71 patients (38.6%). MRI plus mammography combined detected breast cancer in 163 patients (88.6%), increasing the modeled screening sensitivity significantly while reducing specificity (80.3% for the combination vs 93.6% for mammography alone,  $P = .0016$ ).

Annual screening for breast cancer starting between the age of 25 and 30 is recommended for women harboring a mutation in either *BRCA1* or *BRCA2*. In these younger women, an MRI is recommended by the American Cancer Society as a mammogram alone has low sensitivity—about 32% to 39%, according to previous studies—while MRI-based screening has been shown to result in sensitivity between 68% and 100%.

Still, MRIs have well-documented drawbacks including the need for an intravenous contrast agent, lower specificity compared with mammography, higher cost, and a lower sensitivity of ductal carcinoma in situ detection.

The dearth of evidence for specific age groups was the impetus for the current study. It has not been clear whether adding MRI to a mammogram would improve screening, because breast density declines with age—which is thought to increase mammogram sensitivity.

“The independent patient data meta-analysis suggests that women with *BRCA1/2* mutations may still benefit from MRI screening after reaching age 50 years,” concluded the authors.