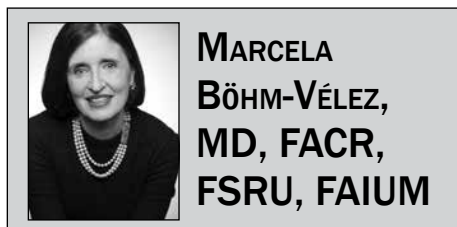

# 3D digital mammography (Digital Breast Tomosynthesis)

Three-dimensional (3D) digital mammography (Digital Breast Tomosynthesis or DBT) has revolutionized breast imaging. The limitations of 2D digital mammography in patients with dense fibroglandular tissue have been described, and sensitivity may be as low as 40 percent for detection of breast cancer. In addition, these patients may require further work up including additional imaging (i.e., mammographic views, ultrasound, MRI) to evaluate asymmetries or architectural distortions causing anxiety. Multiple studies have shown compelling clinical data that 3D mammography technology can provide significant improvements on the most frequently cited limitations of conventional 2D mammography.

A large study published in the *Journal of the American Medical Association* (JAMA) June 25, 2014, "Breast Cancer Screening using 3D digital mammography in combination with 2D digital mammography," was conducted at five leading academic hospitals. Eight community-based sites evaluated more than 450,000 mammography exams. Researchers found that 3D mammography technology finds significantly more (41 percent) invasive breast cancers than 2D mammography, while simultaneously providing a significant (15 percent) decrease in false positives. This allows that invasive cancers may be detected earlier, when treatments are more effective and less



**MARCELA  
BÖHM-VÉLEZ,  
MD, FACR,  
FSRU, FAIUM**

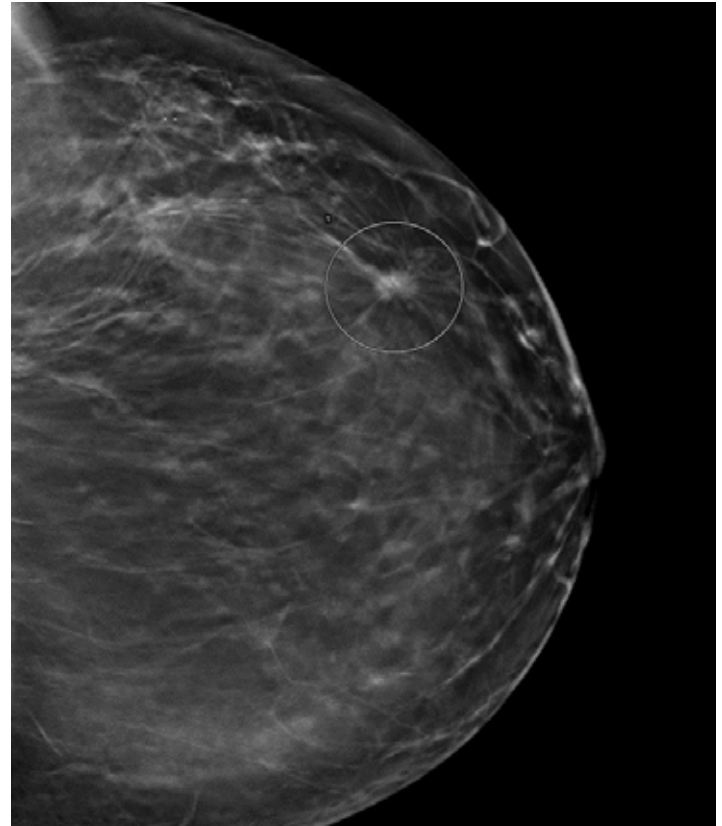
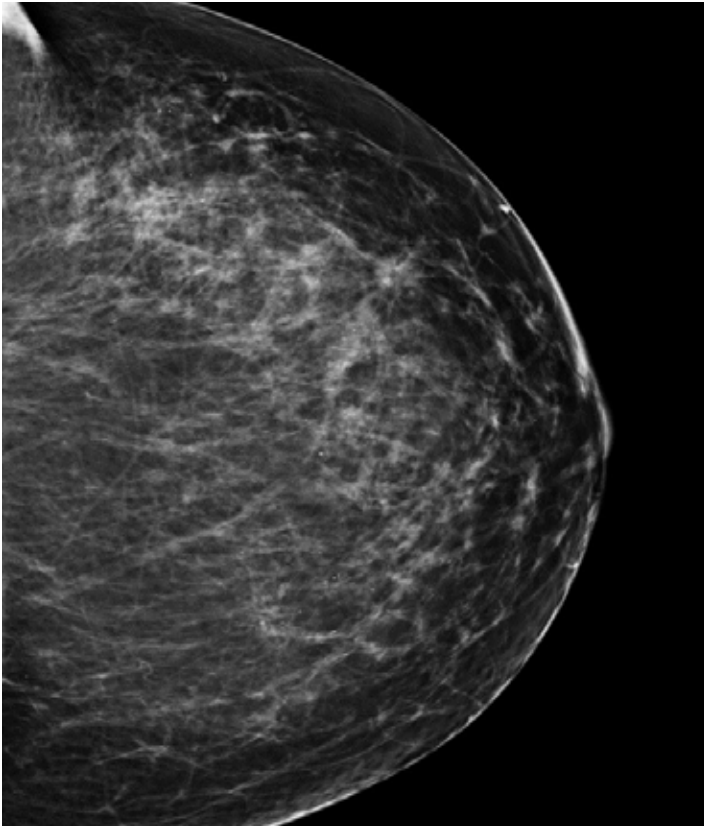
traumatic for patients and not as costly to the health care system. Also, fewer patients will be called back for additional tests, thus reducing the burden of surveillance for referring physicians and preventing undue anxiety for patients. Various studies have confirmed that 3D mammograms can increase detection of earlier stage cancers in all types of breast densities, including the fatty breast.

Tomosynthesis takes a series of low dose X-ray exposures at different angles. The individual images are then reconstructed into a series of high resolution, 1 mm-thick slices which can be displayed on a workstation. The 3D dataset reduces detection challenges associated with overlapping structures in the breast, which is the primary drawback of conventional 2D mammography.

One of the controversies to the use of tomosynthesis, especially for screening, is the increased radiation dose exposure. The average dose of glandular radiation from the many low-dose projections taken during a single acquisition of 3D mammography is roughly the same as that from 2D mammography. Therefore, using

both 2D and 3D doubles the radiation dose to the breast, even though it is still below the acceptable limits of the Mammography Quality Standards Act (MQSA). However, this concern may be obviated using the FDA-approved technology of a synthesized view obtained from the 3D acquisition, eliminating need for the addition of 2D exposures.

In view of the significant increase cost of the unit, service contract, storage of data, time for the radiologist to interpret the more than 1,200 images, the Centers for Medicare and Medicaid Services (CMS) released new codes and values for DBT for 2015. The three new Current Procedural Terminology (CPT®) codes were created as requested by the American College of Radiology (ACR), the American Roentgen Ray Society, and the Radiological Society of North America, and the value approved by the Relative Value Scale Update Committee (RUC). The article published this January in the *Journal of ClinicoEconomics and Outcomes Research* suggests that there is an economic benefit for payers and patients when using tomosynthesis to screen women for breast cancer. Commercial insurers may save at least \$28 for every patient screened with DBT compared to using only 2D mammography. However, we are currently waiting to see if the insurers will pay for this new technology.



**2D                      Craniocaudal views of the left breast                      3D**

**Increased Cancer Detection:** The 2D mammogram of the left breast in a woman with scattered breast tissue was normal; however, the 3D image revealed a small spiculated mass (circled; invasive ductal carcinoma) in the upper outer quadrant of the left breast, allowing treatment to begin earlier.

*Dr. Böhm-Vélez is a radiologist and president of Weinstein Imaging Associates, a private practice focused on women’s imaging with offices in Shadyside, South Hills and North Hills. She also is chair of the Pennsylvania Radiological Society (PRS) Breast Imaging Committee. She can be reached at marcelabvelez@gmail.com.*

**The opinion expressed in this column is that of the writer and does not necessarily reflect the opinion of the Editorial Board, the *Bulletin*, or the Allegheny County Medical Society.**

**References**

1. Skaane P, Bandos AI, Gullien R, et al. Comparison of digital mammography alone and digital mammography plus tomosynthesis in a population-based screening program. *Radiology*. 2013 Apr;267(1):47-56.
2. Zuley ML, Guo B, Catullo VJ, Chough DM et al. Comparison of Two-dimensional Synthesized Mammograms versus Original Digital Mammograms Alone and in Combination with Tomosynthesis Images. *Radiology*. 2014 Jun; 271(3):664-71.
3. Skaane P, Bandos AI, Eben EB, et al. Two-View Digital Breast Tomosynthesis Screening with Synthetically Reconstructed Projection Images: Comparison with Digital Breast Tomosynthesis with Full-Field Digital Mammographic Images, *Radiology*. 2014 Jun;271(3):655-63.
4. Gur D, Zuley ML, Anello MI, et al. Dose reduction in digital breast tomosynthesis (DBT) screening using synthetically reconstructed projection images: an observer performance study. *Acad Radiol*. 2012 Feb;19(2):166-71.
5. Ciatto S, Houssami N, Bernardi D, et al. Integration of 3D digital mammography with tomosynthesis for population breast-cancer screening (STORM): a prospective comparison study. *Lancet Oncol* 2013; 14: 583–89.
6. Durand MA, Haas BM, Yao X, et al. Early Clinical Experience with Digital Breast Tomosynthesis for Screening Mammography. *Radiology*, 2015 Jan, 274: 85–92.
7. Haas BM, Kalra V, Geisel J et al. Comparison of Tomosynthesis Plus Digital Mammography and Digital Mammography Alone for Breast Cancer Screening, *Radiology*, 2013, Dec, 269: 694–700.
8. Bonafede MM, Kalra VB, Miller JD, Fajardo LL. Value analysis of digital breast tomosynthesis for breast cancer screening in a commercially-insured US population. *Journal of ClinicoEconomics and Outcomes Research* 2015 Jan; 7: 53–63.
9. Silva E, How to Code Tomosynthesis, *JACR* 2015 Jan :12: 15.