



The negative predictive value of breast Magnetic Resonance Imaging in noncalcified BIRADS 3 lesions

M.D. Dorrius*, R.M. Pijnappel, P.E. Sijens, M.C. Jansen van der Weide, M. Oudkerk

Department of Radiology, University Medical Center Groningen, University of Groningen, Groningen, The Netherlands

ARTICLE INFO

Article history:

Received 21 October 2010

Accepted 17 December 2010

Keywords:

Breast cancer

Mammography

MRI

BI-RADS

Probably benign lesions

ABSTRACT

Purpose: The purpose of this study is to determine whether breast MRI can provide a sufficient NPV to safely rule out malignancy in mammographic BIRADS 3 lesions.

Materials and methods: In a 3-year consecutive mammographic examination study 176 out of 4391 patients had a lesion classified as BIRADS 3. 76 out of 176 patients underwent breast MRI as diagnostic work-up. Lesions which MRI classified as BIRADS 1 or 2 were considered negative for malignancy. Sensitivity, specificity, PPV and NPV were calculated.

Results: In 27 out of 76 (35.5%) patients MRI showed no enhancement and was classified as BIRADS 1. In 25 (32.9%) patients MRI showed focal or mass enhancement classified as BIRADS 2. In these 52 (68.4%) patients no malignancy was found during at least 2 years study follow-up. The other 24 (31.6%) patients had a lesion classified as BIRADS ≥ 3 . Thirteen of these 24 lesions were malignant by pathology. MRI had a sensitivity of 100% (95% CI: 75–100%), specificity of 82.5% (95% CI: 71–91%), PPV of 54.2% (95% CI: 33–74%) and NPV of 100% (95% CI: 93–100%).

Conclusion: Breast MRI should be used in a diagnostic strategy for the work-up of noncalcified BIRADS 3 lesions. Malignancy is ruled out with a very high level of confidence in the majority of patients (68%), herewith avoiding invasive diagnostic procedures.

© 2010 Elsevier Ireland Ltd. All rights reserved.

1. Introduction

Diagnostic mammography is commonly used to identify possible breast cancers in women and is the primary imaging modality for the early detection of breast cancer. However, mammography has its limitations with regard to both sensitivity (65.6–85.5%) and specificity (87.7–94.3%), which are depended on age and breast density [1,2]. Mammograms are coded using the ordered categories of the American College of Radiology (ACR) Breast Imaging Reporting A Data System (BIRADS) lexicon: category 1: negative; 2: benign finding; 3: probably benign; 4: suspicious finding; 5: highly suggestive of malignancy [3]. The diagnostic work-up of breast lesions depends on the BIRADS classification of the breast lesions. The guideline for non-invasive diagnostic tests for breast abnormalities of the Agency for Health Care Research and Quality in the United States (AHRQ) and the guideline of the National Breast Cancer Consultation in The Netherlands (NABON) state that breast lesions classified as BIRADS 1 and 2 require no further diagnostic work-up or follow-up other than routinely required. The work-up

for a BIRADS 4 or BIRADS 5 lesion demands a biopsy procedure, because the chance of malignancy for a BIRADS 4 lesion varies from 2% to 95% and for a BIRADS 5 lesion higher than 95% [4,5]. The probability of a BIRADS 3 lesion to be malignant is considered to be less than 2%. Therefore, the work-up of a BIRADS 3 lesion can be a biopsy or follow-up mammography after 6 months. In practice, the work-up of BIRADS 3 lesions is decided on the possibilities for biopsy procedures, but also on the wish of the patient and the preference of the clinician. Because of the low predictive value of both physical examination and mammography, a large majority of patients referred for biopsy have a benign lesion [6,7].

Breast Magnetic Resonance Imaging (MRI) is emerging as a clinically useful additional diagnostic tool [5,8], but according to AHRQ the additional value of breast MRI in BIRADS 3 lesion is not yet clear [4,5]. There are sparse data available to support the use of breast MRI as problem solving modality in mammographic BIRADS 3 lesions [9,10] and therefore it has not been implemented in common practice. However, breast MRI has the highest overall sensitivity, which usually exceeds 90% [11–13], of all imaging techniques. In selected populations a negative breast MRI shows a sufficient high negative predictive value (NPV: 91.7–100%) to safely exclude malignancy [9,10,14,15].

The purpose of this study is to determine whether breast MRI can be used as a problem solving modality for mammographic BIRADS 3 lesions by providing a sufficient negative predictive value

* Corresponding author at: Department of Radiology, University Medical Center Groningen, Hanzeplein 1, PO Box 30.001, 9700 RB Groningen, The Netherlands. Tel.: +31 50 3610443; fax: +31 50 3617008.

E-mail address: m.d.dorrius@rad.umcg.nl (M.D. Dorrius).

Table 1
Mammographic BIRADS classification (2005–2008).

BIRADS category	Number of mammography examination
0 need additional imaging evaluation	7 (0.2)
1 negative	89 (2.0)
2 benign finding	3884 (88.4)
3 probably benign	188 (4.3)
4 suspicious abnormality	112 (2.6)
5 highly suggestive of malignancy	111 (2.5)
Total	4391 (100)

Note. Values in parentheses are percentage.

(>98%) for early work-up and there by safely rule out malignancy and to decrease the percentages of invasive procedures.

2. Materials and methods

2.1. Patient population

Patients, referred with clinical suspicious for breast cancer, were included consecutively from January 2005 until January 2008 at the University Medical Center Groningen (UMCG). 4391 patients underwent a mammographic examination and diagnostic work-up at the department of radiology.

Over this period in 188 patients mammograms were classified as BIRADS 3 (Table 1). Twelve women were excluded: 10 patients did not have a work-up in the UMCG and 2 patients died of cardiovascular disease before study follow-up was done. Seventy-six out of 176 patients with a mean age of 52 years (range 30–73 years) underwent a breast MRI as diagnostic work-up of the BIRADS 3 lesion. The final diagnosis was confirmed by pathology or a clinical and diagnostic follow-up of at least 2 years. The remaining 100 patients underwent different work-up strategies (biopsy procedure, surgical intervention, follow-up mammogram or ultrasound) (Fig. 1). This study was approved by the Medical Ethical Committee of the University of Groningen.

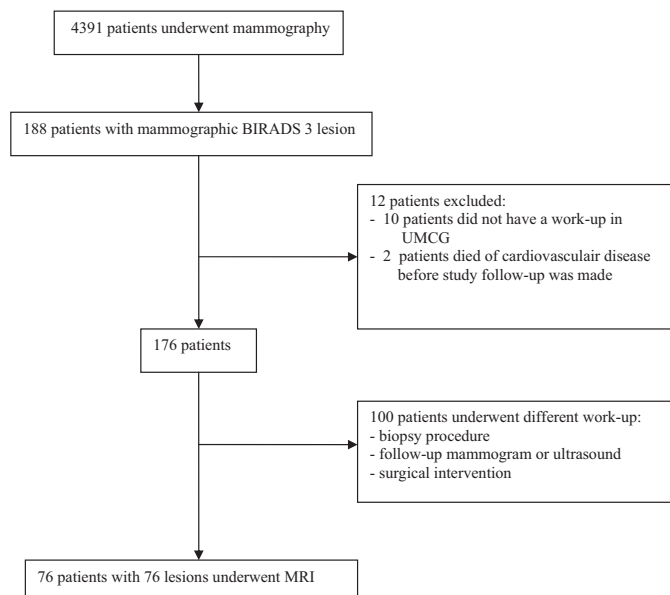


Fig. 1. Flow chart of patient inclusion and with reasons for exclusion.

2.2. Mammography

Mammography was obtained on a mammomat Novation system with a Selenium detector (Siemens Medical Solutions, Erlangen, Germany). In all cases, at least standard mammography was performed in craniocaudal and mediolateral oblique views. The radiologist coded the mammograms by using the ordered categories of the ACR BIRADS lexicon (3). All imaging examinations were assessed by 3 breast radiologists, with at least 10–20 years experience in breast imaging.

2.3. MRI

MR scans were obtained on a 1.5 Tesla whole body MR scanner (Avanto; Siemens Medical Solutions, Erlangen, Germany) using a dedicated bilateral breast coil with the patient in prone position. In cases of premenopausal women, the MRI was performed in the second week of the menstrual cycle. The standard MRI protocol included a T2 Turbo Spin Echo (TR/TE 4500/102 ms, FOV 340 mm and slice thickness 4 mm) in the transversal plane. A T1 weighted three-dimensional (3D) fast low-angle shot (FLASH) sequence (TR/TE/FA 7.5 ms/4 ms/25°, FOV 320 mm and slice thickness 1.50 mm, totally 1.08 min) in the coronal plane was made before and 6 times after Gd intravenous contrast agent (0.2 mmol/kg Dotarem) administration. The contrast-enhanced dynamic sequence was performed approximately 30 s after injection and was followed by 5 additional consecutive sequences. The total duration of the dynamic study was approximately 8 min. Subtracted images were obtained by subtracting pre-contrast images from the post-contrast images using the machines commercially available software. The protocol also included a T1-3D FLASH water excitation (TR/TE/FA 11 ms/3.93 ms/25°, FOV 350 mm, slice thickness 0.90 mm) in the transversal plane. MRI scans were coded using the ordered categories of the ACR BIRADS lexicon [3]. All imaging examinations were assessed by 2 breast radiologists, with at least 10 years experience in breast imaging.

2.4. Image and data analysis

Demography and indication for mammography were obtained from the patient records. In each case the category of findings for which the breast MRI was recommended was analyzed. The mammographic BIRADS 3 findings were noncalcified solid masses, asymmetric densities and microcalcifications [16].

The MR images were classified as normal if no enhancement was seen in the expected location of the mammographic finding (BIRADS 1) or only homogeneous or stippled enhancement was found in the breast, representing normal enhancing breast parenchyma or fibrocystic changes (BIRADS 2). The lesions which were detected on the MRI and corresponded with the area to the mammographic finding were classified as focus, mass enhancement or non-mass enhancement. From the enhancing lesion the location, lesion type, shape, border, distribution, internal enhancement and kinetic curves according to the BIRADS lexicon were assessed and the lesions were classified as BIRADS 3, 4 or 5 [3].

2.5. Statistical methods

Lesions which MRI classified as BIRADS 1 or 2 were considered negative for malignancy. Sensitivity, specificity, positive predictive value (PPV), and negative predictive value (NPV) were calculated on the basis of final pathology reports or long-term clinical and diagnostic follow-up findings of at least 2 years. The 95% confidence intervals (CI) were calculated using the binomial distribution. Receiver operating characteristics (ROC) analysis was used to quantify the diagnostic accuracy of MRI for the assessment of

Table 2
Mammographic BIRADS 3 findings.

Mammographic BIRADS 3 findings	Number
Noncalcified solid mass	56 (73.7)
Asymmetric density	12 (15.8)
Microcalcifications	8 (10.5)
Total	76 (100)

Note. Values in parentheses are percentage.

Table 3
Mammographic BIRADS 3 findings and MRI findings.

Mammographic BIRADS 3 findings	MRI findings			
	No abnormal enhancement	Foci	Mass enhancement	Non-mass enhancement
Noncalcified solid mass (n = 56)	19	22	14	1
Asymmetric density (n = 12)	3	4	5	0
Microcalcifications (n = 8)	5	0	3	0
Total	27 (35.5)	26 (34.2)	22 (29.0)	1 (1.3)

Note. Values in parentheses are percentage.

mammographic BIRADS 3 lesions. Data were analyzed in STATA SE version 11.0 (STATA, College Station, TX) and SPSS (SPSS 16.0 for Windows, SPSS Inc.).

3. Results

3.1. Mammographic and MRI findings

The 76 mammographic BIRADS 3 findings were assessed as a noncalcified solid mass (n = 56, 73.7%), asymmetric density (n = 12, 15.8%) or microcalcifications (n = 8, 10.5%) (Table 2).

In 37 (66.1%) out of 56 mammographic noncalcified solid masses MRI showed an enhancement. These 37 enhancements were foci in 22 (59.5%) patients, mass enhancement in 14 (37.8%) patients and non-mass enhancement in 1 (2.7%) patient. Nineteen (33.9%) mammographic noncalcified solid masses showed no abnormal enhancement on MRI.

In 9 (75%) out of 12 mammographic asymmetric densities were assessed by MRI as foci in 4 (33.3%) patients and as mass enhancement in 5 (41.7%) patients. Three (25.0%) patients had no abnormal enhancement on MRI.

In 5 (62.5%) out of 8 mammographic microcalcifications there was no abnormal enhancement seen on the MRI. Three (37.5%) patients with microcalcifications had a mass enhancement on the MRI (Table 3).

Table 4
MRI BIRADS classification and pathologic proven breast cancer.

	MRI BIRADS category									
	1 (n = 27)		2 (n = 25)		3 (n = 12)		4 (n = 7)		5 (n = 5)	
Number of breast cancers	-	+	-	+	-	+	-	+	-	+
MRI findings										
No abnormal enhancement (n = 27)	27	0								
Foci (n = 26)			21	0	4	0	1	0		
Mass enhancement (n = 22)			4	0	6	2	0	5	0	5
Non-mass enhancement (n = 1)							0	1		
Total	27	0	25	0	10	2	1	6	0	5

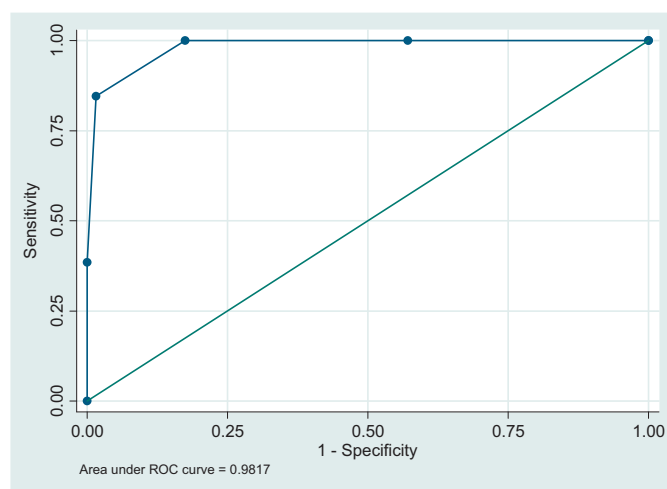


Fig. 2. ROC curve for the accuracy of breast MRI to rule out malignancy in mammographic BIRADS 3 lesions.

3.2. MRI BIRADS category

In 27 (35.5%) out of 76 patients the breast MRI showed no abnormal enhancement in the area corresponding to the mammographic finding and was classified as BIRADS 1. In these patients no malignancy was seen during at least 2 years study follow-up.

In 26 (34.2%) out of 76 patients the MRI showed foci in the breast which were classified as BIRADS 2 in 21 (80.8%) patients and as BIRADS 3 in 4 (15.4%) patients. The study follow-up or pathology of these patients showed no malignancy. In one (3.8%) patient the focus was classified as BIRADS 4. This patient had a surgical excision which showed normal fibroglandular tissue with pathology.

Twenty-two (28.9%) patients had a mass enhancement on the MRI. The mass enhancements were classified as BIRADS 2 in 4 (18.2%) patients, as BIRADS 3 in 8 (36.4%) patients, as BIRADS 4 in 5 (22.7%) patients and as BIRADS 5 in 5 (22.7%) patients. The 4 BIRADS 2 lesions and 6 out of the 8 BIRADS 3 lesions showed no malignancy by study follow-up or pathology. The other masses were malignant by pathology.

In only 1 (1.3%) patient a non-mass enhancement was detected on the MRI. This non-mass enhancement was classified as BIRADS 4 and pathology confirmed malignancy (Table 4).

The breast MRI had a sensitivity of 100% (95% CI: 75–100%), specificity of 82.5% (95% CI: 71–91%), PPV of 54.2% (95% CI: 33–74%) and NPV of 100% (95% CI: 93–100%). ROC analysis revealed an area under the curve (AUC) of 0.91 ± 0.03 (95% CI: 0.85–0.98) for breast MRI in the differentiation between benign and malignant mammographic BIRADS 3 lesions (Fig. 2).

Thirteen (17.1%) out of the 76 mammographic BIRADS 3 lesions were malignant.

3.3. Pathology

In 24 (31.6%) out of 76 patients the final diagnosis was based upon pathology findings of the specimen. Eighteen (75.0%) patients underwent a biopsy procedure and 6 (25.0%) patients a surgical intervention after the MRI scan. Ten (41.7%) out of these 24 patients had invasive ductal carcinoma, 2 (8.2%) patients had an invasive lobular carcinoma and 1 (4.2%) patient had a metaplastic carcinoma. Normal fibroglandular tissue was found in 10 (41.7%) patients and a lipoma was found in 1 (4.2%) patient.

Fifty-two (68.4%) out of 76 patients had a study follow-up of at least 2 years. In these patients no malignant tumor was detected.

4. Discussion

According to the guideline of AHRQ and NABON the diagnostic work-up of mammographic BIRADS 3 lesions should be a biopsy or a follow-up mammography after 6 months [4,5]. In our study, we established that there is a role for breast MRI in mammographic BIRADS 3 lesions, because a non-invasive imaging modality with high NPV can lower the percentage of invasive procedures. The accuracy of the MRI in our study is excellent (AUC 0.91) and the NPV is near to 100% (95% CI: 93–100%). Therefore, further diagnostic work-up is not needed in patients with a breast MRI classified as BIRADS 1 or 2. In our study this is 68.4% (52/76) of the patient group. To our knowledge there is only one other report published which deals with the role of MRI in the evaluation of probably benign lesions (BIRADS 3) in mammography [9]. In this publication a NPV of 100% was reported [9]. Furthermore, other single-center studies, which characterize breast lesions independent on BIRADS classification with MRI, have shown that the NPVs of breast MRI have been as high as 97% [10,14,15].

Kuhl [8] on the other hand described that the evidence for the effectiveness of breast MRI is relatively weak in helping to solve mammographic interpretations problems, because in a multicenter trial of Bluemke et al. the NPV is not high enough to exclude malignancy with sufficient confidence in case of an equivocal or suspicious lesion seen at conventional imaging [11]. The diagnostic accuracy of MRI was studied in 821 patients with a suspicious (BIRADS 4 or 5) mammographic finding (85%) or a suspicious clinical finding with a negative or benign conventional work-up (15%) prior to biopsy [11]. MRI had a negative predictive value of 85% with cancer missed in 48 of 329 negative MRI examinations. Therefore, a biopsy of suspicious mammographic findings (BIRADS 4 or 5) or clinical findings based on the absence of a suspicious MRI correlate cannot be avoided [11]. However, this widely referenced multicenter study was performed in 14 hospitals from 1998 to 2001 and therefore used now outdated MR equipment. Furthermore, Bluemke et al. [11] included microcalcifications of the breast which have negative influence on the NPV. There are 3 studies [17–19] which investigated the role of breast MRI in microcalcifications. The NPV of these studies varies between 76% and 97% which is in accordance with Bluemke results. In our study only 8 patients with mammographic BIRADS 3 microcalcifications underwent MRI. If the MRI showed no abnormal enhancement no malignant lesion were detected by stereotactic biopsy or 2 years study follow-up. However, a definitive conclusion cannot be drawn because our group of microcalcifications is too small.

For mammographic BIRADS 3 lesions it is difficult to decide which work-up strategy (biopsy or follow-up after 6 months) is suitable and thus depending on the preference of the clinician and the wish of the patient. Therefore, in this group it can be expected that MRI has an additional value.

The majority of mammographic BIRADS 3 findings in our study were noncalcified solid masses and asymmetric densities. When

these mammographic lesions in our study showed no abnormality or foci (lesions smaller than 5 mm) on the MRI, malignancy could be excluded. This was in accordance with the publication of Gokalp et al. [9] and Moy et al. [10]. In the report Gokalp report 85% of the 56 mammographic BIRADS 3 lesions were noncalcified shaped lesions or asymmetric densities which were correctly classified as benign [9].

In the study of Moy et al. [10] 115 breasts MRI's were used as adjunctive tool and the findings were correlated with pathology. The equivocal mammographic findings for which MRI was performed were asymmetry without associated microcalcifications (85.2%), architectural distortion (10.4%) and change in the appearance of the site of a previous benign biopsy finding (4.3%). MRI had a sensitivity of 100%, specificity of 91.7%, NPV of 100%, PPV of 40.0% and overall accuracy of 92.2%. Moy et al. concluded that breast MRI could be a useful adjunctive tool when equivocal findings at conventional mammography are asymmetry or architectural distortion [10].

In our study the chance of malignancy in the mammographic BIRADS 3 lesions is approximately 17%. This is considerably higher than is stated in the guideline of AHRQ and NABON (<2%) [4,5]. It is not likely that the high percentage of malignancy is due to the selection of lesions for MRI. Taken into account the total group of 176 BIRADS 3 lesions, also 17.6% ($n=31$) of 176 breast lesions were malignant. This result confirms that classifying lesions in the BIRADS category 3 is difficult with a very high inter- and intraobserver variability in interpretation of mammographic features [20]. Therefore, breast MRI can be helpful in cases of mammographic BIRADS 3 lesions. MRI not only has shown to give near to 100% (95% CI: 93–100%) prediction of benign lesions, which means that no further invasive diagnostic work-up is needed, it also gives a better prediction of malignant lesions assessed as BIRADS 3 on mammogram.

In conclusion, MRI can be used as problem solving modality in non-calcified BIRADS 3 lesions, because the NPV of MRI is high enough to rule out malignancy with sufficient confidence. When the MRI is assessed as BIRADS 1 or 2, no further invasive diagnostic assessment is needed. Further multicenter research is needed to verify and implement these results in regular care.

References

- [1] Barlow WE, Lehman CD, Zheng Y, et al. Performance of diagnostic mammography for women with signs or symptoms of breast cancer. *J Natl Cancer Inst* 2002;94(15):1151–9.
- [2] Carney PA, Miglioretti DL, Yankaskas BC, et al. Individual and combined effects of age, breast density, and hormone replacement therapy use on the accuracy of screening mammography. *Ann Intern Med* 2003;138(3):168–75.
- [3] American College of Radiology (ACR). Illustrated breast imaging reporting and data system (BI-RADS); 1998.
- [4] Nationale Borstkanker Overleg Nederland; NABON versie 1.1; typ: landelijke richtlijn; 2009.
- [5] Agency for Health Care Research and Quality. Effectiveness of non-invasive diagnostic test for breast abnormalities. AHRQ publication no. 06-EHC005-EF, 2006; 2009.
- [6] Kerlikowske K, Grady D, Barclay J, Sickles EA, Ernster V. Likelihood ratios for modern screening mammography. Risk of breast cancer based on age and mammographic interpretation. *J Am Med Assoc* 1996;276(1):39–43.
- [7] Meyer JE, Eberlein TJ, Stomper PC, Sonnenfeld MR. Biopsy of occult breast lesions. Analysis of 1261 abnormalities. *J Am Med Assoc* 1990;263(17):2341–3.
- [8] Kuhl CK. Current status of breast MR imaging. Part 2. Clinical applications. *Radiology* 2007;244(3):672–91.
- [9] Gokalp G, Topal U. MR imaging in probably benign lesions (BI-RADS category 3) of the breast. *Eur J Radiol* 2006;57(3):436–44.
- [10] Moy L, Elias K, Patel V, et al. Is breast MRI helpful in the evaluation of inconclusive mammographic findings? *Am J Radiol* 2009;193(4):986–93.
- [11] Bluemke DA, Gatsonis CA, Chen MH, et al. Magnetic Resonance Imaging of the breast prior to biopsy. *J Am Med Assoc* 2004;292(22):2735–42.
- [12] Hsung JM, Sonnad SS, Schwartz JS, Langlotz CP. Accuracy of MR imaging in the work-up of suspicious breast lesions: a diagnostic meta-analysis. *Acad Radiol* 1999;6(7):387–97.

- [13] Peters NH, Borel Rinkes IH, Zuithoff NP, Mali WP, Moons KG, Peeters PH. Meta-analysis of MR imaging in the diagnosis of breast lesions. *Radiology* 2006;246(1):116–24.
- [14] Kuhl CK, Schmutzler RK, Leutner CC, et al. Breast MR imaging screening in 192 women proved or suspected to be carriers of a breast cancer susceptibility gene: preliminary results. *Radiology* 2000;215(1):267–79.
- [15] Vassiou K, Kanavou T, Vlychou M, et al. Characterization of breast lesions with CE-MR multimodal morphological and kinetic analysis: comparison with conventional mammography and high-resolution ultrasound. *Eur J Radiol* 2009;70(1):69–76.
- [16] Sickles EA. Probably benign breast lesions: when should follow-up be recommended and what is the optimal follow-up protocol? *Radiology* 1999;213(1):11–4.
- [17] Akita A, Tanimoto A, Jinno H, Kameyama K, Kuribayashi S. The clinical value of bilateral breast MR imaging: is it worth performing on patients showing suspicious microcalcifications on mammography? *Eur Radiol* 2009;19(9):2089–96.
- [18] Cilotti A, Iacconi C, Marini C, et al. Contrast-enhanced MR imaging in patients with BI-RADS 3–5 microcalcifications. *Radiol Med* 2007;112(2):272–86.
- [19] Uematsu T, Yuen S, Kasami M, Uchida Y. Dynamic contrast-enhanced MR imaging in screening detected microcalcification lesions of the breast: is there any value? *Breast Cancer Res Treat* 2007;103(3):269–81.
- [20] Ciatto S, Houssami N, Apruzzese A, et al. Reader variability in reporting breast imaging according to BI-RADS assessment categories (the Florence experience). *Breast* 2006;215(1):44–51.