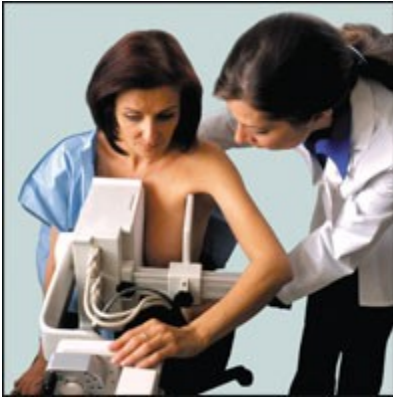


Special Supplement: Advances in Women's Imaging

Building a Case for BSGI

by Amy Lillard



In a recent study, BSGI had the highest sensitivity for the detection of ILC as compared to mammography, sonography, and MRI.

Two new research studies show that for specific cancers and particular situations, breast-specific gamma imaging is a valuable tool.

Breast-specific gamma imaging (BSGI) has been used in more than 60,000 women and has been around for the last decade. But for many physicians, the new imaging tool still has yet to prove its power when it comes to detecting breast cancer. New research is emerging to do just that, pointing the way to a future where BSGI is an instrumental tool in radiologists' and surgeons' tool kits, and demonstrating important situations where BSGI can make a major difference.

A New Imaging Method

BSGI is a new kind of molecular imaging approach, using a Dilon 6800, high-resolution gamma camera and radiotracer. Due to their increased rate of metabolic activity, cancerous cells in the breast absorb more of this tracer. The cancerous areas appear as "hot spots" on the BSGI image.

"Mammography and ultrasound ask, 'What does cancer look like?'" said Rachel Brem, MD, professor of radiology and director of The Breast Imaging and Interventional Center, The George Washington University Medical Center, Washington, DC. Brem is considered one of the world's experts on BSGI, and has been using the technology in research and practice for over 10 years. "BSGI asks how cancer functions. As such, it gives us the ability to harness a different approach to breast cancer diagnosis, based on physiology."

The BSGI technology represents some major potential benefits in the area of breast cancer imaging. The "hot spot" imaging may help physicians identify more cancers as well as potentially increase the reliability of differentiating cancerous from noncancerous

cells over that of other tools. The camera provides a manageable four to 16 images versus the thousands produced by breast MRI. Plus, the technique can improve the viewing of lesions independent of tissue density, and discover cancers in an earlier stage.

It sounds like a story with a happy ending for patients and physicians. But BSGI use has been greeted with a peculiar reaction from many experts in the field. Despite studies showing

credible results and advantages of the tool, many researchers and practicing clinicians view the new technology



BSGI uses a Dillon 6800 high-resolution gamma camera and radiotracer.

with doubt or even disdain. However, the increasing number of studies demonstrating the use of BSGI is helping to turn the tide.

"Breast imagers are not generally nuclear medicine imagers," Brem said. "BSGI requires an entirely different setup and mind-set. I think it is being accepted in greater numbers, but it just takes a while for the general medical community to accept new and powerful technologies. It's especially challenging in this case since the two communities of breast imaging and nuclear medicine are not used to coinciding."

Also contributing to the dragging of feet may be the near universal acceptance and admiration for MRI.

"I think people have delved far into MRI, and those pictures are sexier," said Nathalie Johnson, MD, general surgeon and surgical oncologist at Good Samaritan Hospital, Portland, Ore. "BSGI is not sexy. It's the Ford truck, doing the daily work that needs to be done and is done well. MRI is the Rolls Royce, beautiful and fun. People have done entire fellowships in MRI. So to throw that out, after investing time and money in these expensive machines, and go to something with less of a learning curve can feel unacceptable. Plus, doctors like to see 10 years of studies before they change their practice."

Research Support

Despite the resistance, new studies conducted on BSGI show that a change in practice might just be worth it.

A new study conducted by Brem shows that the "nemesis" cancer originating from the milk-producing glands can be imaged more completely, with higher sensitivity, than other tools. The study was published in the February 2009 issue of the *American Journal of Roentgenology*.

"We focused on invasive lobular carcinoma (ILC) because it is a particularly difficult type of cancer to identify," Brem said. "With its growth pattern, it doesn't present as a ball of cells but an infiltrative process of malignancy. It's not a lump, but just a vague thickening. That's hard to pinpoint on a mammogram or even an MRI scan. It's the nemesis cancer, and we wanted to see the sensitivity of BSGI compared to mammography, sonography, and MRI."

Brem and her team conducted a retrospective multicenter study of women with biopsy-proven ILC; 26 women ranging in age from 46 to 82 years with a total of 28 biopsy-proven ILCs were included in the study group. All patients had undergone mammography and BSGI, and the imaging findings were classified as positive or negative for ILC by experienced breast imagers.

The results were striking. BSGI had the highest sensitivity for the detection of ILC (93%). Mammography, sonography, and MRI showed sensitivities of 79%, 68%, and 83%, respectively.

"This is a less frequent cancer, but one that normally occurs in both breasts and is difficult to accurately identify," Brem said. "It's very important to find this cancer, and BSGI seems to be the most sensitive means of detecting it."

In another critical area of breast cancer imaging, a new study conducted by Johnson demonstrates that women facing a recent breast cancer diagnosis may find additional cancer, in the same or opposite breast, with BSGI testing. The study appeared in the February 2009 issue of the *American Journal of Surgery*.

"As a breast surgeon, I treat many newly diagnosed women with breast cancer, and the critical questions revolve around next treatment steps," Johnson said. "Is the cancer found all that exists? How large is it? Can I effectively do a lumpectomy? We really need to make sure that we have identified the entire and only lesion. But with MRI, the false-positive rate is significant. That can be frustrating and scary for patients, requiring additional biopsies that may not be necessary."

Johnson and her team conducted a retrospective review from two community-based breast imaging centers. Patients were newly diagnosed and had BSGI performed as part of the imaging work-up. A total of 138 patients (69 invasive ductal carcinoma, 20 invasive lobular carcinoma, 32 ductal carcinoma in situ, and 17 mixtures of invasive ductal carcinoma, invasive lobular carcinoma, or ductal carcinoma in situ and other) were reviewed.

BSGI showed its power in the results: 25 patients (18.1%) had a positive BSGI study at a site remote from their known cancer, or more extensive disease than detected from previous imaging; 15 patients (10.9%) were positive for a synchronous or more extensive malignancy in the same or contralateral breast. The positive predictive value for BSGI was 92.9%.

"The key takeaway from the study is this: BSGI does just as good a job as MRI, or better, in this setting," Johnson said. "BSGI provides accurate evaluation of remaining breast tissue in newly diagnosed breast cancer patients with few false-positive readings. We can still pick up additional cancers, but are not distracted by so many additional findings like MRI provides."

BSGI in Clinical Use

With results like these, both physicians advocate for the use of BSGI in a clinical setting. But how best can the imaging and general medical community take advantage of BSGI?

"This is not a replacement for mammography and other methods," Brem said. "BSGI is ideal for high-risk patient screening, and difficult situations like women with implants. Also, at our institution, everyone with newly diagnosed breast cancer gets offered physiologic imaging, with the majority having BSGI. Our surgeons preferentially recommend BSGI to MRI as it is easier for the patient, is equally sensitive with greater specificity and fewer false-positives, and helps us identify other foci of cancer."

Johnson agrees that BSGI is ideal for screening with certain populations, and beneficial with women who have claustrophobia or are morbidly obese. These are currently obstacles with MRI scanning. Another important consideration? Cost-effectiveness.

"BSGI is ultimately cheaper," Johnson said. "It's less expensive than other tools to begin with, but also can help patients avoid the additional biopsies necessary from MRI scanning. That results in much more cost-effective screening."

BSGI continues to be studied, and both Brem and Johnson would like to conduct additional research into specific areas where the technique outperforms others. With compelling research in hand, proponents continue to chip away at the medical community resistance, and hope for a future where BSGI is used to improve breast cancer imaging and patient outcomes.